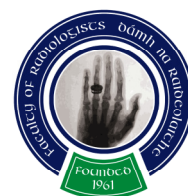



Faculty of Radiologists
Royal College of Surgeons in Ireland



Combined Spring Meeting

March 23rd & 24th 2012

Venue: Mount Juliet, Co. Kilkenny

Programme

**Faculty of Radiologists, Royal College of Surgeons in Ireland CPD Credits
Awarded: 5.5 (Friday: 2 CPD Credits, Saturday: 3.5 CPD Credits)
Royal College of Radiologists credits are applied for.**

Friday 23rd March 2012

2 CPD Credits

3.30-4.30pm **Registration**

4.30-5.30pm

4.30-5.00pm Dr. Steven James
Avoiding mistakes in bone tumour imaging
The Royal Orthopaedic Hospital NHS Foundation Trust

5.00-5.30pm Dr. Orla Buckley
Interstitial lung disease
Adelaide / Meath Hospital

5.30-6.30pm **Moderator:**

Dr. Richard Fitzgerald
What to do if concern is raised about a Radiologist's performance
The Royal Wolverhampton Hospitals NHS Trust

8pm **Dinner**

Saturday 24th March 2012

3.5 CPD Credits

8.30-9.00am Registration

9.00-10.00am **Moderator:**

9.00-9.30am Dr. Marie Staunton
Imaging of the acute abdomen
Mercy University Hospital

9.30-10.00am Dr. David Coughlan
'UTI imaging' clinical point of view
National Children's Hospital, Tallaght

10.00-11.00am **Moderator:**

10.00-10.30am Dr. Tony Geoghegan
Conditions of the female pelvis
Mater Misericordiae University Hospital

10.30-11.00am Dr. Niall Power
CT of chest and abdominal trauma
Waterford Regional Hospital

11.00-11.30am **Tea/Coffee Break and Poster Exhibition**

11.30-12.30pm

Moderator:

11.30-12.00pm

Mr. Martin O Donohoe

Vascular Disease -Surgical Insights for the Radiologist

Mater Misericordiae University Hospital, Dublin

12.00-12.30pm

Dr Mark Elliot

How to interpret the Lumbar spine

Musgrave Park Hospital, Belfast

12.30pm

Ms. Louise Casey

National QA Programme

13.00 pm

Awarding of Prizes

2pm

Golf Competition



Poster Display List

Display No. 1

Immunoglobulin G4-Related Systemic Disease – a Remarkable Imitator of Malignancy

Jan F Gerstenmaier, Stephen J Skehan, Eric J Heffernan, Niall Swan*, Dermot E Malone, Robert G Gibney
Departments of Radiology and Pathology*, St. Vincent's University Hospital, Dublin

Display No. 2

Paediatric Hip sonography – how to do it?

Conal Corbally¹, Anita Tuohy², Declan Sheppard²

¹Department of Orthopaedics, Merlin Park Hospital, Galway

²Department of Radiology, Portiuncula Hospital, Ballinasloe, Galway

Display No. 3

Intraductal Papillary Mucinous Neoplasm: Spectrum of MDCT and MRI appearances.

A M Osborne, R Browne

Adelaide and Meath Hospital Incorporating National Children's Hospital Dublin

Display No. 4

Testis cancer: MDCT staging with histopathological correlation

A M Osborne, Dept. of Radiology, Adelaide and Meath Hospital Incorporating National Children's Hospital Tallaght, Dublin;

J Thornhill, Dept. of Urology, Adelaide and Meath Hospital Incorporating National Children's Hospital Tallaght, Dublin;

W Torreggiani, Dept. of Radiology, Adelaide and Meath Incorporating National Children's Hospital Tallaght, Dublin

Display No. 5

Transarterial Chemoembolisation (TACE) for Hepatocellular Carcinoma (HCC), Extrahepatic Collaterals and complex vascular patterns. A Pictorial Review.

Eoghan McCarthy, Niamh O'Mahony, Conor O'Riordan, Graeme McNeill, Niall McEniff, Michael Guiney, Mark J Ryan.

Radiology Department, St James's Hospital, Dublin

Display No. 6

Calcaneum: normal and abnormal – pictorial presentation

I.Kopecka, N El Saiety, N Ramesh

Radiology Department, Midland Regional Hospital, Portlaoise

Display No. 7

Comparison between empirical versus BMI-based optimisation of tube exposure factors on effective dose in coronary CT angiography

HK Kok¹, B Loo², B Callinan¹, WC Torreggiani¹, O Buckley¹

Departments of Radiology¹ and Cardiology²,

Adelaide & Meath Hospital incorporating the National Children's Hospital, Dublin

Display No. 8

An investigation of variance in published radiological reference dose schedules applied to various clinical groups

OM Delaney, SR McWilliams, M Maher, P McLaughlin

Radiology Department Cork University Hospital, Cork

Display No. 9

Cranial Ultrasound; Indications and Limitations

Alison K Hurley, Umer Salati, Ken Courtney, Martin Ryan

Department of Radiology Adelaide and Meath Hospital Dublin incorporating the National Children's Hospital, Dublin

Display No. 10

Imaging Investigation of Paediatric Macrocephaly

Alison K Hurley, Lucie Furlong, Martin Ryan, Eric Colhoun

Department of Radiology, Adelaide and Meath Hospital Dublin incorporating the National Children's Hospital, Dublin

Display No. 11

The Role of Liver Ultrasound in Peri-operative Staging in Patients with Newly Diagnosed Primary Invasive Breast Cancer

E. Canniff^{1,2}, M. Staunton³, A.O'Donerty^{4,5}

¹ 4th year medical student, School of Medicine, University College Cork

² Radiographer, Radiology Department, St Vincent's University Hospital, Dublin

³ Lecturer, School of Medicine and Healthcare Sciences, University College Dublin

⁴ Consultant Radiologist and Clinical Director, BreastCheck, Dublin

⁵ Consultant Radiologist, Radiology Department, St Vincent's University Hospital, Dublin

St Vincent's University Hospital, Dublin

Display No. 12

Closing the audit loop: impact of introducing whole spine sagittal T2 imaging and gradient echo to the trauma spine MR protocol in the National Spinal Unit.

Colleran GC, Walsh A, Heneghan HM, Craddock A, Kavanagh EC, Poynton AR, Smith E, Lawler LP.

Departments of Radiology and the National Spinal Injuries Unit, Mater Misericordiae University Hospital and the National Rehabilitation Hospital, Dunleary, Dublin.

Display No. 13

Audit of Biopsy Systems Used in Ultrasound Guided Liver Biopsy

M.Crawford Jefferson, R.Lindsay, A.Collins, P.K.Ellis, P.Kennedy

Radiology Department, Royal Victoria Hospital, Belfast

Display No. 14

Cerebral Venous Thrombosis – A radiologist’s perspective.

A.Corr, J. Cunningham, S. Power, J. Pearly-Ti, M. Thornton, P. Brennan, S. Looby. Neuroradiology Department, Beaumont Hospital, Dublin.

Display No. 15

Pseudotumour cerebri (PTC): A review of the Findings on MRI

Kelliher, E., Corr, A., Cunningham, J., Power, S., Thornton, J., Brennan, P., Looby, S. Neuroradiology Department: Beaumont Hospital, Dublin.

Display No. 16

Pictorial Review of the Imaging Features of Spinal Lymphoma.

Looking Beyond the Bones.

J.Cunningham, E. Kelliher, S. Power, J.PTi, M.Thornton, P.Brennan, S.Looby. Department of Radiology, Beaumont Hospital, Dublin

Display No. 17

Evaluating The Role Of MR Imaging In Suspected Cauda Equina Syndrome

Jonathan F Farrell, Barry E Kelly
Imaging Centre, Royal Victoria Hospital, Belfast

Display No. 18

Ischaemic Bowel Imaging Findings

Dr. K Courtney, Dr. S Barrett, Dr. U Salati, Dr. W Torreggiani.
Department of Radiology
Adelaide & Meath Hospital, Dublin (Incorporating the National Children’s Hospital)

Display No. 19

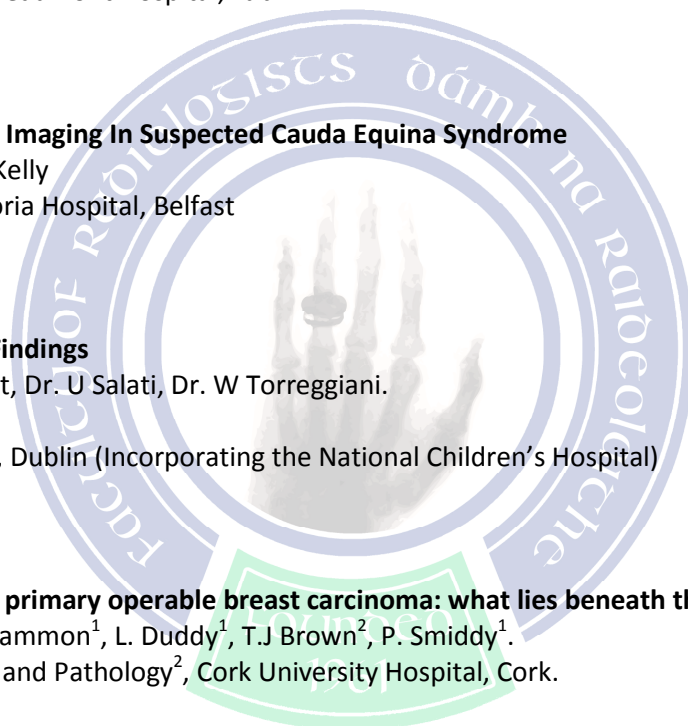
Assessment of the axilla in primary operable breast carcinoma: what lies beneath the normal node?

M. Twomey¹, S. Hayes¹, J. Sammon¹, L. Duddy¹, T.J Brown², P. Smiddy¹.
Departments of Radiology¹ and Pathology², Cork University Hospital, Cork.

Display No. 20

Calcified Cerebral Emboli Resulting in Acute Cerebral Infarction: Imaging Appearances

Long NM, McEvoy CM, Murphy S, Kavanagh EC.
Radiology Department, Mater Misericordiae University Hospital, Dublin



Display No. 21

Effectively of Drapes in the Reduction of Ionising Radiation Hand Scatter Dose in Interventional Radiology.

Catherine B. McConville, Peter K. Ellis, Department of Radiology, Royal Victoria Hospital, Belfast, Co. Antrim.

Display No. 22

Ultrasound guided interventions of the foot and ankle: a review of technique and clinical outcomes.

English C, Ward J, Cafferty F, Kearns S. Bergin D.

Radiology Department, Galway University Hospital, Galway.

Display No. 23

Incidental distal oesophageal pathology on CT of the thorax and its correlation with endoscopy: A pictorial review

Umer Salati, Alison Hurley, Ken Courtney, William Torreggiani

Radiology Department, Adelaide & Meath incorporating the National Children's Hospital, Dublin

Display No. 24

Incidence of Pulmonary Embolus in CT Venogram Studies positive for Iliofemoral Deep Venous Thrombosis.

Fergus Cafferty¹, Gerard O Sullivan¹

1. Radiology, UCH, Galway, Galway, Galway.

Display No. 25

Don't miss the Woods for the Trees": A Pictorial Review of Clinically Important Non-spinal findings detected on Spinal MR Imaging

K. Lyons, J. Sorensen, S. Looby

Department of Neuroradiology, Beaumont Hospital, Dublin

